

## Prevention of trismus with different pharmacological therapies after surgical extraction of impacted mandibular third molar

Edin Selimović<sup>1,2</sup>, Lejla Ibrahimagić-Šeper<sup>1,2</sup>, Ibrahim Šišić<sup>2,3</sup>, Suad Sivić<sup>2,4</sup>, Senad Huseinagić<sup>2,4</sup>

<sup>1</sup>Public Institution Healthcare Center Zenica, <sup>2</sup>Faculty of Health, University of Zenica, <sup>3</sup>Cantonal Hospital Zenica, <sup>4</sup>Institute for Health and Food Safety Zenica; Zenica, Bosnia and Herzegovina

### ABSTRACT

**Aim** To assess prevention and reduction of trismus after surgically extracted impacted mandibular third molars with individual and combined therapy with corticosteroids and anti-inflammatory analgesics.

**Methods** The research included 60 randomly selected patients (3 groups) attended to the Dental Oral Surgery of the Public Institution Healthcare Center Zenica during the period January-December 2008. Patients of both genders, 18-45 years of age, were presented without pain and other inflammatory symptoms at the time of surgery. According to a scheme established in the research protocol, two medications were administered orally: methylprednisolone (corticosteroid) 32 mg and meloxicam (non-steroidal anti-inflammatory analgesic, NSAID) 15 mg as a single drug, or a combination of both drugs. The level of trismus is assessed on the basis of differences of preoperative and postoperative values of interincisal spaces when fully opening the mouth on the second and the seventh post-operative day. The differences between groups of patients were evaluated by means of Tukey's HSD test.

**Results** On the second and on the seventh post-operative day significantly better results were registered in the group that received only corticosteroids and in the group that received both, corticosteroids and NSAIDs compared to the group that received only NSAIDs. A tendency of trismus reduction was present in all patient groups for the second and seventh day after surgery.

**Conclusion** Prevention and control of postoperative trismus after surgical extraction of impacted mandibular third molars with combined therapy is effective and superior comparing to individual therapy with meloxicam-or methylprednisolone alone.

**Key words:** impacted wisdom teeth, corticosteroids, analgesic drug

### Corresponding author:

Edin Selimović  
Public Institution Health Center Zenica  
Fra Ivana Jukuća 2,  
72 000 Zenica, Bosnia and Herzegovina  
E-mail: drselimovic@yahoo.com

### Original submission:

02 August 2016;

### Revised submission:

05 August 2016;

**Accepted:** 08 August 2016.

doi: 10.17392/871-16

## INTRODUCTION

First signs of the development of third molars can be detected on the radiograph at the age of six, and in some people at the age 12 to 14 (1). Their appearance usually takes place over a period between 17-25 years of age. Since wisdom teeth are the last teeth that appear in the jaw, they often remain impacted due to lack of space (2).

The term impacted (retained) teeth means that teeth are fully formed in the bone but have not grown in their place or in any place in the dental arch or outside of it (3).

Oral surgical removal of impacted mandibular third molar is associated with possible postoperative complications (4). These can be expected and predictable, such as swelling, pain, trismus, or serious and permanent complications, such as paresthesia n. alveolaris inferior, n. lingualis and fracture of the mandible (5). The depth of impacted tooth and age of the patient as well as the duration of the surgical procedure may be associated with an increase in the incidence of postoperative complications (6). It is expected that the removal of impacted mandibular third molars often has a more pronounced negative impact on quality of life in the first 4 -7 days after surgical intervention, but after that period it is followed by improving quality of life, most notably in terms of reduction of post-operative pain, swelling and trismus (7-10).

Previous research indicates that through pharmacological control the volume of the inflammatory process, the intensity of postoperative trismus can be significantly reduced (11).

Obvious interactivity between the mechanisms of non-steroid anti-inflammatory analgesics and corticosteroids suggests that a combined therapy can provide significant weakening of the expected post-operative sequelae such as trismus with absence of adverse reactions in relation to a specific therapy (12).

The aim of our research was comparison of treatment effects, i.e. prevention of the development of postoperative trismus through a combined therapy with non-steroid anti-inflammatory analgesics and corticosteroids, as well as with individual treatment with these medications after oral surgical treatment of removal of impacted mandibular third molars, based on monitoring of parameters triz\_T2 (trismus on the second post-

operative day) and triz\_T7 (trismus on the seventh postoperative day).

## PATIENTS AND METHODS

### Patients and study design

The prospective research included 60 patients of both genders (68.33% females and 31.67 males) aged 18-45 admitted at the Healthcare Center Zenica during the period January-December 2008, because of an indication for surgical extraction of impacted mandibular third molar (53.33% of the left and 46.67% right impacted mandibular third molars). All patients were without pain and other inflammatory symptoms including swelling, hyperemia and reduced mouth opening, with an indication for surgical extraction of impacted mandibular third molar with fully completed growth and development of roots, and mesio-angular position (Winter II class). The same surgical approach with standard surgical instruments and uniform corticotomy on vestibular side was adopted for each patient.

Patients were (randomly) divided into three groups according to administrated therapy, i. e., methylprednisolone, meloxicam, methylprednisolone + meloxicam. In each group there were 20 patients of both sexes aged 18 to 45 without contraindications to medications and anesthetics that were planned to be used in the research.

Group I- patients treated with individual treatment meloxicam. Every patient received 1x15mg of the drug an hour before the surgery, and also in the next two days.

Group II- patients treated with methylprednisolone therapy. Each patient was given 1x32 mg of the drug an hour before the surgery and 1x32 mg 12 hours after the surgery.

Group III - patients treated with the combination therapy of meloxicam and methylprednisolone. Every patient in this group received 1x15 mg meloxicam an hour before surgery, and in the next two days; also, the patients was given 1x32 mg methylprednisolone an hour before surgery and 1x32 mg methylprednisolone 12 hours after the surgery.

No patient included in the study had any side effects such as nausea, vomiting, dizziness, temperature, allergic reactions.

For each patient preoperatively an appropriate measure was taken, and precise description of the position, angulation, depth of impacted molars was recorded based on the analysis of panoramic radiographs. Precise description of the wounds, sutures and current state of healing in the postoperative period was also recorded. Each patient was fully informed about the research protocol and gave a written consent to perform the study.

Exclusion criteria were: kidney or liver disease, blood dyscrasia, previous and present gastric ulcers, heart disease, demonstrated hypersensitivity, allergic reactions to some research medicine, pregnancy and lactation. The research did not include patients who had not undergone preoperative measurement or did not accept the necessary measurements during the planned control on the second and seventh day after the surgical treatment, or patients who had taken painkillers or anti-inflammatory medications within 24 hours before the surgical treatment, and patients with noticeable postoperative bleeding. Patients who voluntarily changed the treatment plan were also excluded from the study.

Based on a decision of the School of Dental Medicine in Sarajevo, the Ethics Committee of the Healthcare Center Zenica approved the study, which was conducted at the Oral Surgery Section of the Dentistry Department of the Health Center Zenica.

## Methods

Impacted teeth in patients were extracted under local anesthesia in a dose of 4 cc 2% Xylocaine with adrenaline (1: 80,000) with prior consent of patients.

Two medications were used: meloxicam 15 mg (nonsteroidal anti-inflammatory drugs from the group of selective COX-2 inhibitors) and methylprednisolone 32 mg (glucocorticoid of synthetic origin). Both medications were applied *per os*, according to the administration schedules (13).

The level of trismus was assessed in relation to *triz\_T2* parameters (size of trismus on the second postoperative day) and *triz\_T7* (size of trismus on the seventh postoperative day), and they were created on the basis of the difference between preoperative and postoperative values of interincisal spaces.

## Statistical analysis

Pearson's correlation coefficient evaluated interdependence parameters for trismus for the second and seventh postoperative day. The level of statistical significance was  $p < 0.05$ .

A two-way analysis variance for one independent variable (three groups of respondents) and two dependent variables (trismus second and seventh day) was performed comparing patients and measurements at different time points. In order to find a statistically significant difference between arithmetic means of individual groups (I, II and III) and the time of measurement Tukey HSD test was used. Tukey HSD test was conducted comparing the results of the group (I, II and III) patients and test of statistical significance, the parameters *trizl\_T2* and *trizl\_T7*. Mean differences indicate the mean difference in the parameters of trismus between individual therapy or a group of patients. The standard error is an error differences between individual therapy or group of patients. Confidence interval of 95% is the interval indicating the mean value of difference between values with 95% accuracy.

## RESULTS

The correlation of results for all three groups of patients for the parameters *triz\_T2* and *triz\_T7* was significant (0.939;  $p < 0.01$ ).

The high value of Pearson's correlation coefficients ( $p < 0.01$ ) for the parameters *triz\_T2* (size of trismus on the second postoperative day) and *triz\_T7* (size of trismus on the seventh postoperative day) suggests a statistically significant difference  $p < 0.05$  among the groups of patients (I, II and III) and a strong link between *triz\_T2* and *triz\_T7*. This means that those patients who had a strong postoperative trismus on the second day had stronger trismus on the seventh postoperative day.

For group of patients with respect to the parameters *triz\_T2* and *triz\_T7* showed that the groups differed significantly ( $p < 0.05$ ). Statistically significant difference ( $p < 0.05$ ) was found among the groups I, II and III of patients for the parameters *triz\_T2* and *triz\_T7*. The tendency of trismus reduction was presented in all patient groups with regard to the second and seventh postoperative day. The pace of reduction was not statistically significantly different among the groups.

**Table 1. Comparison of groups I, II and III with respect to trismus parameters**

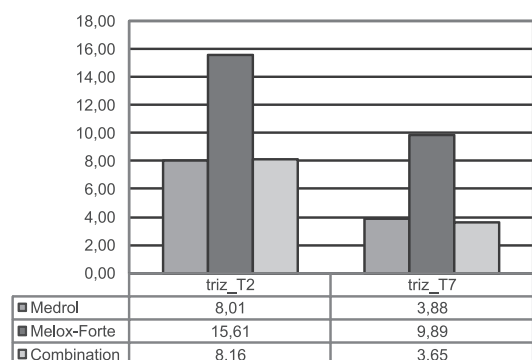
Trismus parameters	Group of patients*	Groups of patients compared with which	Mean differences	95% confidence interval
triz_T2	II	I	-7.59850†	-8.6941
		III	-.15100	-1.2466
	I	II	7.59850†	6.5029
		III	7.44750†	6.3519
	III	II	.15100	-.9446
		I	-7.44750†	-8.5431
triz_T7	II	I	-6.00500	-6.8349
		III	.23050	-.5994
	I	II	6.00500†	5.1751
		III	6.23550†	5.4056
	III	II	-.23050	-1.0604
		I	-6.23550†	-7.0654

\*Group I, patients with individual treatment meloxicam; Group II- patients with individual methylprednisolone therapy; Group III - patients with combination therapy of meloxicam and methylprednisolone

†Value of difference with the level of significance 0.05 (Tukey's HSD test)

Statistically significant difference ( $p < 0.05$ ) between the groups with individual therapy with methylprednisolone and individual therapy with meloxicam for the parameters triz\_T2 and triz\_T7 was found, and it was in favor of the therapy with methylprednisolone (Table 1). There was a statistically significant difference ( $p < 0.05$ ) between the groups with individual therapy with melox fortae and combined therapy with methylprednisolone and meloxicam for the parameters triz\_T2 and triz\_T7 and it is in favor of the combined therapy (Table 1). There was also difference between the groups with individual therapy with methylprednisolone and combined therapy with methylprednisolone and meloxicam for the parameters triz\_T2 and triz\_T7 and it is in favor of combined therapy, but without statistical significance (Table 1).

Figure 1 presents trismus level for the second and seventh postoperative day to three groups of patients with mean values for each groups.



**Figure 1. The level of trismus for the second and seventh postoperative day for three groups of patients with mean values for each group**

## DISCUSSION

In our research, the size of trismus was largest for the group which received individual therapy with meloxicam. Trismus level was lower for the therapy with metilprednisolone compared to therapy with meloxicam. A statistically significant reduction in the size of trismus in the group which received a combined therapy with metilprednisolone and meloxicam, compared to the group that received therapy with meloxicam was found. We did not find a statistically significant difference in size of trismus between the group with combined therapy and individual therapy with metilprednisolone. Postoperative trismus was lower with combined therapy with metilprednisolone and meloxicam compared to individual therapy with metilprednisolone. Unlike Bamgbose et al. who compared the effect of joint action of corticosteroid dexamethasone and non-steroidal anti-inflammatory analgesic diclofenac K compared to individual therapy with non-steroid anti-inflammatory analgesic diclofenac K, our research demonstrated a statistically significant difference in reduction of trismus between these two medication protocols in favor of the combined therapy (14).

Mico-Llorens et al. have determined the efficacy of corticosteroid methylprednisolone in controlling postoperative sequelae after surgical removal of impacted mandibular third molars applying 40 mg of methylprednisolone and found a statistically significant levels of swelling, trismus and pain on the second and seventh postoperative day as compared to the control group (15). Lopez C et al. compared the efficacy of corticosteroid methylprednisolone versus non-steroid anti-inflammatory analgesic diclofenac in the treatment of inflammation and trismus after surgical removal of third molars, but there were no statistically significant differences in the development of trismus for the used anti-inflammatory therapy (16).

Buyukkurt et al. found that patients who received the combination of prednisolone-diclofenac had a smaller loss of the ability to open their mouth on the second and seventh postoperative day compared with the group that received prednisolone and the control group (17). Bjornsson et al. in their study compared the postoperative course after removal of identical bilateral impacted mandibular molars (18) and significantly higher trismus was

observed after the first surgery with respect to the second surgery, although the surgical protocol was identical for all surgical interventions, and the duration of the procedure was about the same. Recent literature suggests that, in addition to giving painkillers, corticosteroids should be given to prevent the expected postoperative sequelae in oral surgery, especially for the reduction of postoperative edema and trismus. There are numerous studies about their pharmacokinetic and pharmacodynamic properties (19-21). Cortisol and synthetic analogs of cortisol have the ability to impede physiology of inflammation process, but the mechanisms through which corticosteroids can alleviate pain are incompletely understood. Suppression of tissue levels of bradykinin (22) that increase nociception in inflamed tissue by applying systemic glucocorticoids, was confirmed in numerous studies (23). A decrease of synthesis of prostaglandins was found due to corticosteroids which might contribute to analgesia (24) However, the primary effect of corticosteroids analyzed in a number of studies manifested in the effective reduction of swelling, and the impact on trismus was significant, while the impact on the level of pain was secondary (25-28).

Trismus is normal and expected after the surgery of third molars. Limited opening of the mou-

th after oral surgical removal of impacted third mandible molars is caused by a combination of several factors such as pain, hematoma, edema, muscle and tendon injuries (29). Patients who were given corticosteroids for edema control also showed a decreasing tendency of trismus (30). Trismus evolves slower than swelling and reaches its maximum after 2-3 days (31). Postoperative pain and trismus may be connected, implying that the pain is the cause of reduced ability to open the mouth after the surgery of third molars (32). Patients with no pain may have trismus. Several studies indicate a link between swelling and trismus (33), but one study has shown that there is no such a connection (34).

The results of this study are consistent with previous studies. Prevention and control of postoperative trismus after surgical extraction of impacted mandibular third molars with the combination therapy is effective. The combination therapy is superior to individual therapy with a single meloxicam with methylprednisolone alone.

#### FUNDING

No specific funding was received for this study.

#### TRANSPARENCY DECLARATION

Conflict of interest: None to declare.

#### REFERENCES

1. Costa MG, Pazzini CA, Pantuzo MC, Jorge ML, Marques LS. Is there justification for prophylactic extraction of third molars? A systematic review. *Braz Oral Res* 2013; 27:183-8.
2. Lee CT, Zhang S, Leung YY, Tsang CC, Chu CH. Patients' satisfaction and prevalence of complications on surgical extraction of third molar. *Patient Prefer Adherence* 2015; 9:257-63.
3. Jiang Q, Qiu Y, Yang CJ, Chen M, Zhang Z. Piezoelectric versus conventional rotary techniques for impacted third molar extraction: a meta-analysis of randomized controlled trials. *Medicine (Baltimore)* 2015; 94:e1685.
4. Adeyemo WL, James O, Ogunlewe MO, Ladeinde AL, Taiwo OA. Indications for extraction of third molars: a review of 1763 cases. *Niger Postgrad Med J* 2008; 15:42-6.
5. Carrasco-Labra A, Brignardello-Petersen R, Yanine N, Araya I, Guyatt G. Secondary versus primary closure techniques for the prevention of postoperative complications following removal of impacted mandibular third molars: a systematic review and meta-analysis of randomized controlled trials. *J Oral Maxillofac Surg* 2012; 70:e441-57.
6. Coulthard P, Bailey E, Esposito M, Furness S, Worthington HV. Surgical techniques for the removal of mandibular wisdom teeth. *Cochrane Database Syst Rev* 2014; CD004345.
7. Ghaemina H. Coronectomy may be a way of managing impacted third molars. *Evid Based Dent* 2013; 14:57-8.
8. Gelesko S, Long L, Faulk J, Phillips C, Dicus C, White RP Jr. Cryotherapy and topical minocycline as adjunctive measures to control pain after third molar surgery: an exploratory study. *J Oral Maxillofac Surg* 2011; 69:e324-32.

9. Msagati F, Simon EN, Owibingire S. Pattern of occurrence and treatment of impacted teeth at the Muhimbili National Hospital, Dar es Salaam, Tanzania. *BMC Oral Health* 2013; 6:13-37.
10. Osunde O, Saheeb B, Bassey G. Indications and risk factors for complications of lower third molar surgery in a Nigerian teaching hospital. *Ann Med Health Sci Res* 2014; 4:938-42.
11. Chaudhary PD, Rastogi S, Gupta P, Niranjana Prasad Indra B, Thomas R Choudhury. Pre-emptive effect of dexamethasone injection and consumption on post-operative swelling, pain, and trismus after third molar surgery. A prospective, double blind and randomized study. *J Oral Biol Craniofac Res* 2015; 5:21-7.
12. Beirne OR. Corticosteroids decrease pain, swelling and trismus. *Evid Based Dent* 2013; 14:111.
13. Selimović E. The effect of corticosteroids and non-steroidal anti-inflammatory analgesics in the postoperative recovery of impacted mandibular third molars. University of Sarajevo, 2009; MA Thesis.
14. Bamgbose BO, Akinwande JA, Adeyemo WL, Ladeinde AL, Arotiba GT, Ogunlewe MO. Effects of co-administered dexamethasone and diclofenac potassium on pain, swelling and trismus following third molar surgery. *Head Face Med* 2005; 1:11.
15. Micó-Llorens JM, Satorres-Nieto M, Gargallo-Albiol J, Arnabat-Domínguez J, Berini-Aytés L, Gay-Escoda C. Efficacy of methylprednisolone in controlling complications after impacted lower third molar surgical extraction. *Eur J Clin Pharmacol* 2006; 62:693-8.
16. Lopez Carriches C, Martinez Gonzalez JM, Donado Rodriguez M. The use of methylprednisolone versus diclofenac in the treatment of inflammation and trismus after surgical removal of lower third molars. *Med Oral Patol Oral Cir Bucal* 2006; 11:E440-5.
17. Buyukkurt MC, Gungormus M, Kaya O. The effect of a single dose prednisolone with and without diclofenac on pain, trismus, and swelling after removal of mandibular third molars. *J Oral Maxillofac Surg* 2006; 64:1761-6.
18. Bjornsson GA, Bjornland T, Skoglund LA. Reproducibility of postoperative courses after surgical removal of symmetrically impacted wisdom teeth. *Methods Find Exp Clin Pharmacol* 1995; 17:345-56.
19. Atkinson HC, Currie J, Moodie J, Carson S, Evans S, Worthington JP, Steenberg LJ, Bisley E, Frampton C. Combination paracetamol and ibuprofen for pain relief after oral surgery: a dose ranging study. *Eur J Clin Pharmacol* 2015; 71:579-87.
20. Akbulut N, Üstüner E, Atakan C, Çölok G. Comparison of the effect of naproxen, etodolac and diclofenac on postoperative sequelae following third molar surgery: a randomised, double-blind, crossover study. *Med Oral Patol Oral Cir Bucal* 2014; 19:e149-56.
21. Herrera-Briones FJ, Prados Sánchez E, Reyes Botella C, Vallecillo Capilla M. Update on the use of corticosteroids in third molar surgery: systematic review of the literature. *Oral Surg Oral Med Oral Pathol Oral Radiol* 2013; 116:e342-51.
22. Hatgreaves KM, Costello A. Glucocorticoids suppress levels of immunoreactive bradykinin in inflamed tissue as evaluated by microdialysis probes. *Clin Pharmacol Ther* 1990; 48:168-78.
23. Marques J, Pié-Sánchez J, Figueiredo R, Valmaseda-Castellón E, Gay-Escoda C. Effect of the local administration of betamethasone on pain, swelling and trismus after impacted lower third molar extraction. A randomized, triple blinded, controlled trial. *Med Oral Patol Oral Cir Bucal* 2014; 19:e49-54.
24. Li C, Men Y, Li L. Discrepancies on dexamethasone for trismus after third molar extraction. *Oral Surg Oral Med Oral Pathol Oral Radiol* 2014; 117:253.
25. Ngeow WC, Lim D. Do Corticosteroids still have a role in the management of third molar surgery? *Adv Ther* 2016; 33:1105-39.
26. Dodson TB. Corticosteroid administration in oral and orthognathic surgery. *Evid Based Dent* 2011; 12:49-50.
27. Ehsan A, Ali Bukhari SG, Ashar, Manzoor A, Junaid M. Effects of pre-operative submucosal dexamethasone injection on the postoperative swelling and trismus following surgical extraction of mandibular third molar. *J Coll Physicians Surg Pak* 2014; 24:489-92.
28. Warraich R, Faisal M, Rana M, Shaheen A, Gellrich NC, Rana M. Evaluation of postoperative discomfort following third molar surgery using submucosal dexamethasone - a randomized observer blind prospective study. *Oral Surg Oral Med Oral Pathol Oral Radiol* 2013; 116:16-22.
29. Jain NK, John RR. Anesthetic efficacy of 4% articaine versus 2% lignocaine during the surgical removal of the third molar: A comparative prospective study. *Anesth Essays Res* 2016; 10:356-61.
30. Alexander RE, Thronson RR. A review of perioperative corticosteroid use in dentoalveolar surgery. *Oral Surg Oral Med Oral Pathol Oral Radiol Endod* 2000; 90:406-15.
31. Morse Z, Tump A, Kevelham E. Ibuprofen as a pre-emptive analgesic is as effective as rofecoxib for mandibular third molar surgery. *Odontology* 2006; 94:59-63.
32. Sotto-Maior BS, Senna PM, de Souza Picorelli Assis NM. Corticosteroids or cyclooxygenase 2-selective inhibitor medication for the management of pain and swelling after third-molar surgery. *J Craniofac Surg* 2011; 22:758-62.
33. Berge TI. Visual analogue scale assessment of postoperative swelling. A study of clinical inflammatory variables subsequent to third-molar surgery. *Acta Odontol Scand* 1988 ; 46:233-40
34. Pedersen A. Interrelation of complaints after removal of impacted mandibular third molars. *Int J Oral Surg* 1985; 14:241-4.

## Prevenција trizmusa različitim terapijskim pristupom kod hirurške ekstrakcije impaktiranog mandibularnog umnjaka

Edin Selimović<sup>1,2</sup>, Lejla Ibrahimagić-Šeper<sup>1,2</sup>, Ibrahim Šišić<sup>2,3</sup>, Suad Sivić<sup>2,4</sup>, Senad Huseinagić<sup>2,4</sup>

<sup>1</sup>JU Dom zdravlja, Zenica, <sup>2</sup>Zdravstveni fakultet, Univerzitet u Zenici, <sup>3</sup>Kantonalna bolnica, Zenica, <sup>4</sup>Institut za zdravlje i sigurnost hrane, Zenica; Zenica, Bosna i Hercegovina

### SAŽETAK

**Cilj** Procjena prevencije i smanjenja trizmusa nakon operativnim putem ekstrahiranih impaktiranih mandibularnih umnjaka kod pojedinačne i kombinirane terapije s kortikosteroidima i antiinfalamtornim analgeticima.

**Metode** U istraživanje je metodom slučajnog izbora bilo uključeno 60 pacijenata (3 grupe) koji su posjetili Oralnu hirurgiju JU Dom zdravlja Zenica, u periodu od januara do decembra 2008. godine. Svi kandidati, oba spola, od 18 do 45 godina starosti, bili su bez prisustva bola i drugih inflamatornih simptoma u vrijeme operativnog zahvata. Prema shemi utvrđenoj protokolom istraživanja, ordinirana su „per os“ dva lijeka: methylprednisolone 32 mg i meloxicam 15 mg. Nivo trizmusa je procjenjivan na osnovu razlike preoperativne i postoperativne vrijednosti interincizalnog razmaka. Razlike između grupa pacijenata u nivou trizmusa procjenjivane su posredstvom Tukeyevog HSD-testa.

**Rezultati** Ustanovljena je statistički značajna razlika ( $p < 0,05$ ) za smanjenje postoperativnog trizmusa između grupe pacijenata kojoj je ordinirana kombinirana terapija i grupa pacijenata kojima je ordinirana pojedinačna terapija. Tendencija smanjenja trizmusa je prisutna u svim grupama pacijenata s obzirom na drugi i sedmi postoperativni dan.

**Zaključak** Prevencija i suzbijanje postoperativnog trizmusa nakon hirurške ekstrakcije impaktiranih mandibularnih umnjaka s kombiniranom terapijom je učinkovita i superiornija u odnosu na individualnu terapiju s metilprednizolonom ili meloksikamom.

**Ključne riječi:** impaktirani treći molari, kortikosteroidi, analgetici